



PATIENT

Spirit Edwards

SPECIES

Feline

BREED

DMH

SEX

Female Spayed

AGE

15 years

WEIGHT

10.38lbs

INTERPRETED BY

Maggie Machen
Lamy, DVM
DACVIM (Cardiology)

IMAGING PERFORMED BY

Pamela Harrigan,
RDCS

HOSPITAL NAME

Mass Veterinary Services

REFERRING VET

Dr. Masloski

INVOICE

28390

DATE

1/17/23

PRESENTING CLINICAL SIGNS

History: Spirit is referred to evaluate a heart murmur. A thyroid level at that time was 3.1. She is eating well with normal activity. On exam: NSR, grade II/VI parasternal murmur, PSS, lung fields clear, compressible thorax, mm pink, moist, CRT<2. BP: 130 mmHg x 5. *No sedation for study.

ECHOCARDIOGRAM FINDINGS

2D, m-mode, color flow and Doppler imaging is available.

Left ventricle: The LV diameter is normal with adequate myocardial function. The LV wall thicknesses are largely normal. There is a diffusely hyperechoic endocardium consistent with mild fibrosis. The endocardium appears mildly remodeled. The papillary muscles are mildly remodeled and hyperechoic.

Left atrium: The left atrium is normal in dimension. No obvious spontaneous contrast or thrombi seen.

Mitral valve: The mitral valve is normal in structure and mobility. No obvious systolic anterior motion is seen.

Aortic valve/aorta: The aortic valve is normal in morphology and mobility. Normal aortic outflow velocity; laminar flow. No aortic insufficiency.

Right ventricle: Normal right ventricular diameter and morphology indicating no overt evidence of pulmonary arterial hypertension.

Right atrium: The right atrium is normal in dimension.

Tricuspid valve: The tricuspid valve appears normal with trace tricuspid regurgitation.

Pulmonic valve/pulmonary artery: The pulmonic valve is normal in morphology and mobility. No pulmonic insufficiency. Normal RVOT velocity; laminar flow.

Pericardium/other: No pericardial or pleural effusion noted. No obvious cardiac masses.

Heart rhythm: ECG reveals a sinus rhythm with an average HR of 230bpm.

2-Dimensional Measurements

Ao diam (cm)	1.0
LA diam (cm)	1.2
LA:Ao (Swe)	1.2
IVS thickness (cm)	0.35
LVID diastole (cm)	1.2
PW thickness (cm)	0.37
LVID systole (cm)	0.66
FS (%)	50

Doppler Measurements

PV Vmax (m/s)	0.56
AoV Vmax (m/s)	1.1
MR Vmax (m/s)	NA
TR Vmax (m/s)	NA
TR PG (mmHg)	NA

INTERPRETATION OF THE FINDINGS

Essentially normal cardiac structure and function. The LV wall thickness is normal and there is no evidence of elevated left atrial pressure. There is mild remodeling and fibrosis of the left ventricular wall, which is considered normal. No cause for the murmur is identified in this study, making it likely physiologic in origin (i.e., secondary to tachycardia, volume changes, etc.).

RECOMMENDATIONS

- Given these findings, no medications are indicated.
- No cardiac contraindication for general anesthesia. Mild IV fluid restriction is advised.



PATIENT

Spirit Edwards

SPECIES

Feline

BREED

DMH

SEX

Female Spayed

AGE

15 years

WEIGHT

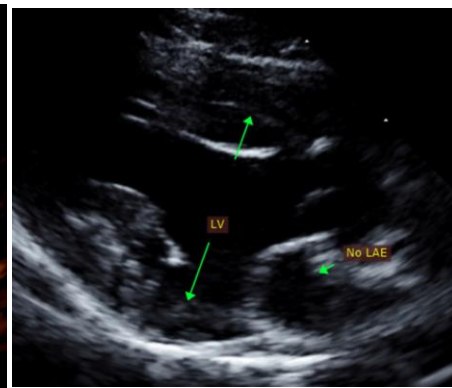
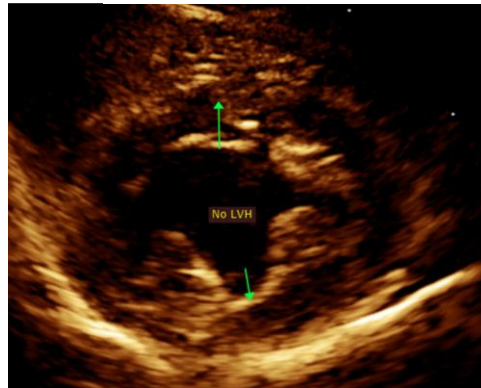
10.38lbs

- Risk for complication with steroid use typically follows LA dilation, which in this case is low. That being said, any cat can experience unexpected signs of intolerance and monitoring of RR/RE is advised particularly in the initiation phase.
- Monitor for any clinical evidence of cardiac compromise, including respiratory changes and/or signs of a blood clot event (paralysis, neurologic changes, etc).

PLAN

- Recommend recheck echocardiogram in 1 year to reassess murmur origin and screen for development of disease the pre-existing murmur may mask.

IMAGES



INTERPRETED BY

Maggie Machen
Lamy, DVM
DACVIM (Cardiology)

The information and recommendations provided are based on the images presented by the referring veterinarian. No evaluation can be communicated regarding pathology that was not visible in the image/video clips provided.

Thank you for this referral. This report was generated using transcription software, and minor dictation errors may be present. If the clinical or image interpretation does not parallel your findings or if I can be of any further assistance, please contact me.

IMAGING PERFORMED BY

Pamela Harrigan,
RDCS

Maggie Machen Lamy, DVM

Diplomate of the American College of Veterinary Internal Medicine (Cardiology)
info@sonopath.com

HOSPITAL NAME

Mass Veterinary Services

Echocardiogram performed by:

Pamela Harrigan, RDCS
Pet Animal Ultrasound Service (4paus.com)

REFERRING VET

Dr. Masloski

INVOICE

28390

DATE

1/17/23